

Lyme Disease Associated with Unilateral Interstitial Keratitis

Michael J. Miyashiro, M.D., Pharm.D., Richard W. Yee, M.D.,
Ghanshyam Patel, M.D., and Richard S. Ruiz, M.D.

Purpose. To report a case of Lyme disease that presented with a single nummular unilateral interstitial keratitis. **Methods.** Case report and review of the literature. **Results.** A 57-year-old black man who had contact with freshly killed deer had a chief complaint of foreign-body sensation in his right eye (OD) that had been diagnosed and treated for herpes simplex stromal keratitis. The patient underwent a systemic workup for interstitial keratitis. All results including RPR and MHA-TP were negative except for Lyme antibody titer (enzyme-linked immunosorbent assay [ELISA]) 178 U/ml (normal, <159 U/ml). **Conclusion.** Interstitial keratitis from Lyme disease has been regarded as a bilateral disease in the literature. We present this infrequent ocular manifestation of Lyme disease as a rare single nummular unilateral presentation.

Key Words: Interstitial—Keratitis—Lyme disease—Unilateral.

The most common tick-transmitted illness in the United States is caused by the spirochete *Borrelia burgdorferi*, which causes Lyme disease. Ophthalmologists must be aware of the ocular manifestations associated with this infection, which include episcleritis, conjunctivitis, blepharitis, iritis, choroiditis, macular and disc edema, pseudotumor cerebri, endophthalmitis, and interstitial keratitis (IK), all previously described in the literature (1,2).

IK is a nonsuppurative inflammatory response of the entire corneal stromal thickness, which does not involve the corneal epithelium and may or may not involve the endothelium. When associated with Lyme disease, IK may present with multiple opacities usually 0.25 mm in diameter and occur months to years after the *B. burgdorferi* inoculation (3). In review of the literature, IK

caused by Lyme disease has been commonly described as a bilateral disease (2,4,5). Other diseases that are also known to cause bilateral IK include congenital syphilis and Cogan's syndrome. The common causes of unilateral IK include *Mycobacterium tuberculosis* and *leprae*, Rubella, Epstein-Barr virus, *Chlamydia trachomatis*, Leishmaniasis, *Onchocerca volvulus*, and acquired syphilis.

CASE REPORT

A 57-year-old black man was referred to our cornea clinic for a corneal lesion in his right eye (OD). The patient had been treated for >1 year for presumed herpes simplex stromal keratitis without success and was subsequently referred to the cornea clinic with the diagnosis of unilateral IK.

The patient denied any history of sexually transmitted diseases, problems with hearing, vertigo, or tinnitus. He also denied any history of chronic cough, night sweats, or positive purified protein derivative skin test. He could not recall any skin rash, insect bites, fever, chills, or malaise. Additionally, he denied stiff neck or myalgias.

His medical and surgical history was unremarkable except for occasional joint aches in his right hand. He was not taking medication and denied drug allergies. Family history was unremarkable. The patient worked with freshly killed deer on a regular basis, directly handling and transporting the deer to a processing plant.

On ophthalmic examination, visual acuity without correction (VA sc) was OD, 20/40; pinhole, 20/30; and left eye (OS), 20/20. Near vision with correction at 14 inches was OD, J2; and OS, J1. Manifest refraction was OD, $-0.75 + 2.25 \times 165$ (20/25-1); and OS, $-0.25 + 0.75 \times 180$ (20/20-2). Intraocular pressures were OD/OS, 20/22 mm Hg at 2:45 p.m. External examination was within normal limits. Extraocular movements were full in both eyes (OU). Pupils were 4 mm OU without a relative afferent pupillary defect OU. Corneal sensation was in-

Submitted May 12, 1998. Revision received July 8, 1998. Accepted July 31, 1998.

From Department of Ophthalmology and Visual Science, The University of Texas Medical School at Houston, Houston, Texas, U.S.A.

Address correspondence and reprint requests to Dr. R.W. Yee, The University of Texas Medical School at Houston, Department of Ophthalmology and Visual Science, Hermann Eye Center, 6411 Fannin, 7th Floor, Houston, TX 77030, U.S.A.

tact OU. Slit-lamp examination was significant for trace injection of the conjunctiva and a single, 2-mm full stromal nummular infiltrate with a 0.3-mm corneal epithelial erosion, which stained with fluorescein at 6 o'clock OD on the border of the visual axis (Fig. 1). The rest of the slit-lamp examination was otherwise unremarkable OU. Fundusoscopic examination revealed a cup-to-disc ratio of 0.2, normal disc, macula, vessels, and periphery OU.

Laboratory results revealed CBC with differential and erythrocyte sedimentation rate (ESR) (7 mm/h) to be within normal limits. RPR and MHA-TP were nonreactive. Rheumatoid factor, antinuclear antibody, C-ANCA, P-ANCA, ACE, PPD, and viral and bacterial cultures were all negative. However, Lyme titer (enzyme-linked immunosorbent assay [ELISA]) was 178 U/ml (>159 U/ml positive).

The diagnosis of Lyme disease was made and presumed the etiology of this patient's IK. The patient was treated with tetracycline, 250 mg 4 times a day, for 21 days and followed up weekly. There was complete resolution of the corneal erosion; however, a 0.1-mm stromal corneal scar remains.

DISCUSSION

The differential diagnosis of IK includes syphilis, tuberculosis, leprosy, Cogan's syndrome, and Lyme dis-

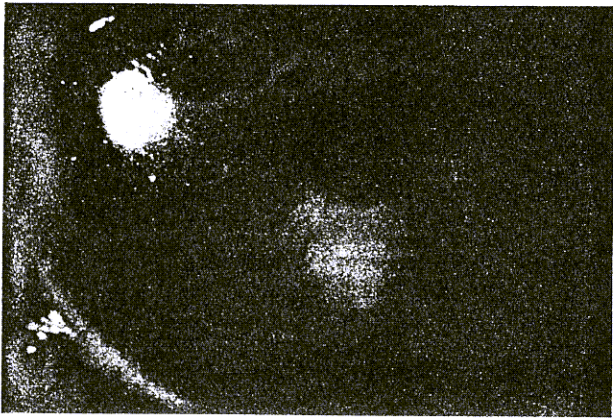


FIG. 1. Right eye, 2.0-mm stromal infiltrate with 0.3-mm central epithelial erosion.

ease. Lyme disease may cause ocular complications affecting various ocular structures and may or may not affect vision occurring during any of the three stages of the disease. It is most commonly associated with a mild transient conjunctivitis that occurs during stage I (dermatologic) along with flu-like symptoms (3). The serologic diagnosis is identified by either ELISA, immunofluorescent antibody (IFA), or Western blot. False negatives are seen in the initial 2–4 weeks of the infection. False-positive ELISA serology is not uncommon, being reported in many laboratories throughout the United States, but can be minimized by additionally performing the Western blot (6). However, if the Lyme serology is positive, a negative *Treponema pallidum* (MHA-TP) and rapid plasma reagin (RPR) for syphilis strongly suggests Lyme disease (3), as in our patient. Systemic treatment is typically oral or intravenous penicillin, tetracycline, or erythromycin. The keratitis of Lyme disease has been reported to respond to topical corticosteroids (7), which were not instituted in this case.

Although this patient could not recall a skin rash, which may have represented erythema migrans, or any systemic manifestations that are commonly experienced in borreliosis, there have been accounts of patients with relapsing courses of IK without these signs or symptoms (2). This case report demonstrates that IK can be seen after infection with *B. burgdorferi* as only a single nummular unilateral IK.

REFERENCES

1. Flach AJ, Lavoie PE. Episcleritis, conjunctivitis, and keratitis as ocular manifestations of Lyme disease. *Ophthalmology* 1990;97(8):973–5.
2. Karma A, et al. Diagnosis and clinical characteristics of ocular Lyme borreliosis. *Am J Ophthalmol* 1995;119(2):127–35.
3. Park M. Ocular manifestations of Lyme disease. *J Am Optom Assoc* 1989;60(4):284–9.
4. Baum J, Barza M, Weinstein P, Groden J, Aswad M. Bilateral keratitis as a manifestation of Lyme disease. *Am J Ophthalmol* 1988;105:75–7.
5. Kornmehl EW, Lesser RL, Jaros P, Rocco E, Steere AC. Bilateral keratitis in Lyme disease. *Ophthalmology* 1989;96:1194–7.
6. Pachner AR, Ricalton NS. Western blotting in evaluating Lyme seropositivity and the utility of a gel densitometric approach. *Neurology* 1992;42(11):2185–92.
7. Kauffmann DJ, Wormser GP. Ocular Lyme disease: case report and review of the literature. *Br J Ophthalmol* 1990;74:325–7.